

HYPERTENSIVE RETINOPATHY

Roland E. Schmieder

Department of Nephrology and Hypertension, University of Erlangen-Nürnberg, Germany

Introduction

The first description of retinal abnormalities in hypertensive subjects by Liebreich [1] and Gunn [2] dates back to the 19th century. The traditional classification system of hypertensive retinopathy is based on the pioneering work by Keith, Wagner, and Barker in 1939, in which the prognostic significance of funduscopic abnormalities in hypertensive patients was demonstrated [3]. Subsequently, the impact of funduscopic findings on risk stratification was supported by several studies that were conducted in the 1950s and 1960s [4, 5]. Nowadays, funduscopy still plays a major role in the management and risk stratification of hypertensive patients: The ESH/ESC 2007 Guidelines consider hypertensive retinopathy grade 3 and 4 as target-organ damage [6].

Pathophysiology and clinical manifestations

Retinal circulation undergoes a series of pathophysiological changes in hypertension [7]. These changes are mediated either directly by elevated blood pressure or indirectly via vasoactive substances (angiotensin II, endothelin-1, and decreased basal nitric oxide activity among others). Mild changes are reflected by vasoconstriction (generalized and focal arteriolar narrowing), growth of smooth muscle cells, and hyaline degeneration of the wall of the retinal arterioles (opacification of arteriolar walls with widening and accentuation of the central light reflex, also described as silver or copper wiring) as well as changes in the arteriolar and venular junctions (arteriovenous nicking). Advanced changes include breakdown of the blood-retina barrier of the retinal arterioles (haemorrhages, hard exudates, and cotton-wool spots), micro- and macro-aneurysms, and optic disc swelling (papilloedema).

Classification

In their famous work of 1939, Keith, Wagener, and Barker categorized the signs of hypertensive retinopathy into 4 grades of increasing severity (Table 1) and demonstrated that, at that time, hypertensive patients with grade 4 retinopathy had a 3 year survival rate of 6%, as opposed to a survival rate of 70% in those with grade 1 retinopathy [3].

The usefulness of the four-grade classification system of Keith, Wagener, and Barker and the five stage classification of Scheie [8] and its importance in current clinical practice has been questioned repeatedly in recent years [9, 10]. The criticism refers especially to hypertensive retinopathy grade 1 and 2. Low retinopathy grades

(grade 1 and grade 2 signs) cannot easily be distinguished even by experienced investigators because of high inter- and intra-observer variability [11, 12]. Only advanced hypertensive retinopathy grades can be reliably assessed. However, nowadays most hypertensive patients reveal low retinopathy grades (e.g. generalized retinal arteriolar narrowing), whereas few patients have advanced hypertensive retinopathy. Moreover, retinopathy signs do not necessarily correlate with the severity of hypertension, and the positive and negative predictive values between hypertensive retinopathy and blood pressure are low [6, 12].

Prognostic significance

Recent studies evaluating fundus findings and their relation to systemic disease, such as the Blue Mountains Eye Study, the Atherosclerosis Risk in Communities (ARIC) Study, the Multi-Ethnic Study of Atherosclerosis, and the Beaver Dam Eye Study, have demonstrated the value of fundus findings and their association with the risk of hypertension and associated comorbidities [9, 13]. There is solid evidence that signs of advanced hypertensive retinopathy, such as isolated micro-aneurysms, haemorrhages, hard exudates, and cotton-wool spots, are strongly associated with subclinical cerebrovascular disease and predict stroke, coronary artery disease, congestive heart failure, and cardiovascular mortality, independently of blood pressure and other traditional risk factors [9, 10]. In contrast, the impact of mild hypertensive retinopathy signs such as generalized and focal arteriolar narrowing and arteriovenous nicking on systemic vascular disease and cardiovascular mortality is less stringent [9, 10].

Recent approaches in imaging technologies

In parallel to the repeated criticism concerning the traditional classification systems for current management of hypertensive patients, new methodological approaches have been developed focusing on the more precise and reliable assessment of early retinal arteriolar abnormalities in hypertensive patients, with the aim of improve the diagnostic and prognostic power of mild hypertensive retinopathy [10, 13].

Arteriole-to-venule ratio of retinal vessels

The ability to digitize retinal photographs allows the assessment of outer arteriolar and outer venule diameter of retinal vessels and subsequent calculation of the arteriole-to-venule ratio [14]. The measurement of the arteriole-to-venule ratio of retinal vessels is based on the concept that a lower arteriole-to-venule ratio of retinal vessels reflects general arteriolar narrowing which in turn represents an early step of hypertension-related retinal vascular alterations. Some but not all large population-based studies identified the arteriole-to-venule ratio to be predictive of cardiovascular events [9, 15]. However, no study so far has revealed that the arteriole-to-venule ratio of retinal vessels has a clearly independent value of predicting cardiovascular or total mortality [9, 15]. Recent data indicate that the outer venule diameter is also changed in several metabolic conditions that are frequently associated with hypertension [16], which may dilute the prognostic power of the arteriole-venule ratio. Nevertheless, the arterio-to-venule ratio may serve as a screening tool for cardiovascular risk patients and has also been found to predict the development of hypertension.

Wall-to-lumen ratio of retinal arterioles

The development of scanning laser Doppler flowmetry (SLDF) with automatic full-field perfusion imaging analysis (AFFPIA) allows precise assessment of retinal arteriolar structure and remodelling by

Table 1. Keith-Wagener-Barker classification of hypertensive retinopathy (adapted from [13])

	Grade 1	Grade 2	Grade 3	Grade 4
Arteriolar narrowing	+	++	+++	++++
Arteriovenous nicking		+	++	+++
Retinal haemorrhages			+	++
Micro-aneurysms			+	++
Hard exudates			+	++
Cotton-wool spots			+	++
Optic disc swelling				+
Macular oedema				+

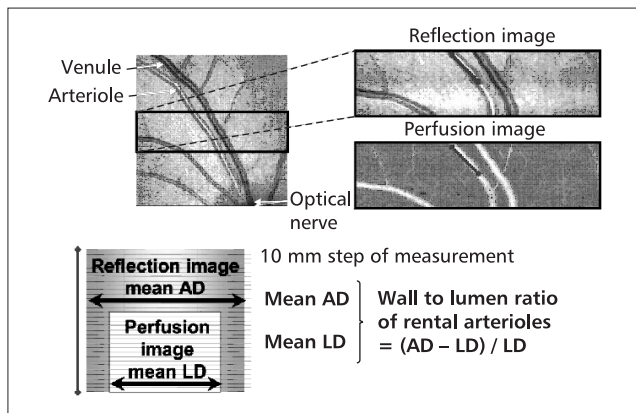


Figure 1. Assessment of the wall-to-lumen ratio of retinal arterioles [19]. A specific length of the arteriole reflecting one heart beat (one systole plus one diastole) is considered for analysis, and diameters every $10\ \mu\text{m}$ of this specific length are measured. Outer diameters (AD) are measured in reflection images and inner diameters (LD) are measured in perfusion images. The mean of the measured diameters is finally calculated and the average from 3 singular measurements is computed for further analysis

analyzing the outer and inner diameters of retinal arterioles and subsequent assessment of the wall-to-lumen ratio, wall thickness, and wall cross-sectional area (volume of vascular wall per unit of length) of the retinal arteriole, as previously described in detail [17–19]. In brief, the outer diameter of the retinal arteriole is assessed in reflection images and the inner diameter is assessed in perfusion images and the wall-to-lumen ratio is then calculated according to the formula (outer diameter–inner diameter/inner diameter) (Fig. 1) [17, 18]. The assessment of the wall-to-lumen ratio of retinal arterioles with SLDF with AFFPIA was found to be reliable [18].

Studies analyzing the arteriolar structure of vessels obtained through biopsies of subcutaneous tissue from abdominal and gluteal regions have clearly demonstrated the remodelling of resistance arterioles and small arteries in subjects with arterial hypertension. Increased wall-to-lumen ratio of arterial vessels indicates an early (probably the earliest) form of hypertension-related atherosclerotic vascular changes and is of prognostic significance in hypertensive patients, with adverse prognosis in those with the greatest wall-to-lumen ratio

[20]. An increase in the wall-to-lumen ratio of retinal vessels can be the result of vasoconstriction, growth of vascular smooth muscle cells, or both [21, 22]. Recent data suggest that retinal arterioles and subcutaneous small arterioles undergo the same type of remodelling in hypertension, and the pattern and quantity of vascular changes are comparable. [19] Thus, it is reasonable to hypothesize that the assessment of the retinal arteriolar structure and remodelling by assessment of the retinal arteriolar wall-to-lumen ratio may serve as a potential future parameter of target organ damage in hypertension. A distinct advantage of studying retinal vessels is the non-invasive nature of the procedure, while subcutaneous vessels are studied by biopsy.

The prognostic value of remodelling of the small arteries taken from biopsies has been already proven [23, 24]. So far, only a few studies have examined the retinal arteriolar structure in hypertension. In untreated patients with stage 1 and 2 essential hypertension, a close relation between systolic and diastolic blood pressure and wall-to-lumen ratio of retinal arterioles was found independently from potential confounding factors including classical cardiovascular risk factors, urinary albumin excretion, sodium intake, and basal nitric oxide activity [19]. Moreover, wall-to-lumen ratio of retinal arterioles was found to be greater in patients with essential hypertension compared to normotensive controls [19]. Hypertensive patients with a history of a cerebrovascular events reveal a greater wall-to-lumen ratio of retinal arterioles than hypertensive and normotensive controls [18]. Treated hypertensive subjects with poor blood pressure control were found to have a greater wall-to-lumen ratio of retinal arterioles than those with better blood pressure control [18]. Moreover, the wall-to-lumen ratio of retinal arterioles was found to be associated with other parameters of target organ damage including intima-media-thickness of carotid artery [25] and urinary albumin excretion. No study so far has been conducted to evaluate the prognostic value of the wall-to-lumen ratio of retinal arterioles.

Conclusions and perspective

There is solid evidence that advanced and, to a lesser extent, mild retinopathy is of prognostic significance for future cardiovascular events. None of the prospective trials had adequately corrected for concurrent measures of hypertensive target organ damage. New methodologies that determine hypertensive retinal vascular changes earlier and more precisely are on the horizon and may serve as tools for detecting hypertensive retinopathy in its early stages.

References

- Liebreich R. Ophthalmoskopischer Befund bei Morbus Brightii. Albrecht von Graefes Arch Ophthalmol 1859; 5: 265–268.
- Gunn RM. Ophthalmoscopic evidence of (1) arterial changes with chronic renal diseases and (2) of increased arterial tension. Trans Ophthal Soc UK 1892; 12: 124–125.
- Keith NM, Wagener HP, Barker NW. Some different types of essential hypertension: their course and prognosis. Am J Med Sci 1939; 197: 332–343.
- Breslin DJ, Gifford RW Jr., Fairbairn JF 2nd, Kearns TP. Prognostic importance of ophthalmoscopic findings in essential hypertension. JAMA 1966; 195: 335–338.
- Frant R, Groen J. Prognosis of vascular hypertension; a 9-year follow-up study of 418 cases. Arch Intern Med (Chic) 1950; 85: 727–750.
- Mancia G, De Backer G, Dominiczak A, et al. 2007 Guidelines for the Management of Arterial Hypertension: The Task Force for the Management of Arterial Hypertension of the European Society of Hypertension (ESH) and of the European Society of Cardiology (ESC). J Hypertens 2007; 25: 1105–1187.
- Tso MO Jampol LM. Pathophysiology of hypertensive retinopathy. Ophthalmology 1982; 89: 1132–1145.
- Scheie HG. Evaluation of ophthalmoscopic changes of hypertension and arteriolar sclerosis. AMA Arch Ophthalmol 1953; 49: 117–138.
- Wong TY, Mitchell P. Hypertensive retinopathy. N Engl J Med 2004; 351: 2310–2317.
- Schmieder RE. Hypertensive retinopathy: a window to vascular remodeling in arterial hypertension. Hypertension 2008; 51: 43–44.
- Dimmitt SB, West JN, Eames SM, Gibson JM, Gosling P, Littler WA. Usefulness of ophthalmoscopy in mild to moderate hypertension. Lancet 1989; 1: 1103–1106.
- van den Born BJ, Hulsman CA, Hoekstra JB, Schlingemann RO, van Montfrans GA. Value of routine funduscopy in patients with hypertension: systematic review. BMJ 2005; 331: 73.
- DellaCroce JT, Vitale AT. Hypertension and the eye. Curr Opin Ophthalmol 2008; 19: 493–498.
- Hubbard LD, Brothers RJ, King WN, et al. Methods for evaluation of retinal microvascular abnormalities associated with hypertension/sclerosis in the Atherosclerosis Risk in Communities Study. Ophthalmology 1999; 106: 2269–2280.
- Porta M, Grosso A, Veglio F. Hypertensive retinopathy: there's more than meets the eye. J Hypertens 2005; 23: 683–696.
- Nguyen TT, Wong TY. Retinal vascular manifestations of metabolic disorders. Trends Endocrinol Metab 2006; 17: 262–268.
- Michelson G, Welzenbach J, Pal I, Harazny J. Automatic full field analysis of perfusion images gained by scanning laser Doppler flowmetry. Br J Ophthalmol 1998; 82: 1294–1300.
- Harazny JM, Ritt M, Baleanu D, et al. Increased wall:lumen ratio of retinal arterioles in male patients with a history of a cerebrovascular event. Hypertension 2007; 50: 623–629.
- Ritt M, Harazny JM, Ott C, Schlaich MP, Schneider MP, Michelson G, Schmieder RE. Analysis of retinal arteriolar structure in never-treated patients with essential hypertension. J Hypertens 2008; 26: 1427–1434.
- Park JB, Schiffrin EL. Small artery remodeling is the most prevalent (earliest?) form of target organ damage in mild essential hypertension. J Hypertens 2001; 19: 921–930.
- Heagerty AM, Aalkjaer C, Bund SJ, Korsgaard N, Mulvany MJ. Small artery structure in hypertension. Dual processes of remodeling and growth. Hypertension 1993; 21: 391–397.
- Intengan HD, Schiffrin EL. Vascular remodeling in hypertension: roles of apoptosis, inflammation, and fibrosis. Hypertension 2001; 38: 581–587.
- Rizzoni D, Porteri E, Boari GE, et al. Prognostic significance of small-artery structure in hypertension. Circulation 2003; 108: 2230–2235.
- Mathiassen ON, Buus NH, Sihm I, et al. Small artery structure is an independent predictor of cardiovascular events in essential hypertension. J Hypertens 2007; 25: 1021–1026.
- Baleanu D, Ritt M, Harazny J, Heckmann J, Schmieder RE, Michelson G. Wall to lumen ratio of retinal arterioles and arteriole to venule ratio of retinal vessels in patients with cerebrovascular damage. Invest Ophthalmol Vis Sci 2009, Apr 1 [epub ahead of print].